East Lancashire Hospitals NHS
NHS Trust

EXAMPLES OF THE GREAT MIMICKERS OF BREAST CARCINOMA AND THEIR SONOGRAPHIC APPEARANCES

SAMANTHA WEST

Breast carcinomas can take on a multitude of appearances, but many have certain characteristics that display the features of a true carcinoma. These being : shape, orientation,echo pattern and posterior features.[1,2,3]

However, some benign entities can mimic these appearances on ultrasound.
This pictorial review demonstrates some of the great mimickers that display the worrying features.

DIABETIC MASTOPATHY

This is a disease with fibro inflammatory process of the breast. In histology, the breast is shown to be composed of dense stromal keloid-like fibrosis with or without lymphocytic infiltration and interlobular epithelioid fibroblasts.Clinical history of type 1 and long standing type 2 diabetes mellitus is significant. [3,4]

Clinically, diabetic mastopathy often presents as a hard painless irregular breast mass that can also be multiple and bilateral - 60% of cases. These findings are often suspicious and thus referred for imaging.[4]

On ultrasound the appearances can be described as as an irregular poorly defined hypoechoic mass, measuring between 2 and 6 cm in size with posterior acoustic shadowing.[4]

Ref (5) : Example image below

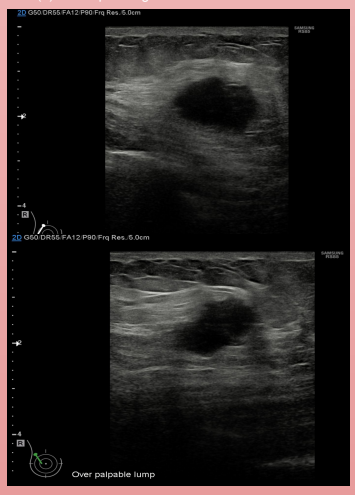

FAT NECROSIS

Fat necrosis often occurs in fatty pendulous breasts. Though it is presumed to be traumatic in origin, a history of injury may only be forthcoming in less than half of patients if no previous surgery is indicated.[1,2,6]

Known as a benign, non-suppurative inflammatory process. This process occurs due to breast trauma. Some of the common causes are : radiotherapy, surgery or trauma.
Clinically and on imaging it can be difficult to distinguish fat necrosis from malignancy.[2,6,7]

There are two forms of fat necrosis, depending on the reaction of the surrounding breast tissue, and they differ clinically, mammographically and sonographically.

Sonographic features of fat necrosis can vary considerably. These being from a solid mass, a complex mass with mural nodules, a complex mass with posterior enhancement or an anechoic mass with posterior shadowing or even an isoechoic mass. [2,3,6,7]

When the fat necrosis stimulates a fibrotic response, it can present as firm fixed mass that can also cause skin tethering/retraction and retraction of the nipple thus mimicking a carcinoma. The other type forms an oil cyst due to the release of free lipids without causing a surrounding reaction[6,7].

Sonographically, fat necrosis surrounded by a fibrous reaction can mimic the appearance of a scirrhous breast carcinoma. Post operative scars do not usually have a nidus but, if accompanied by fat necrosis, they may have a hypoechoic central nidus consisting of fibrous tissue that has been replaced with necrotic fat. The surrounding fibrosis can therefore cause an irregular disorting mass with posterior shadowing. [6,7]

REF (8) Example image below

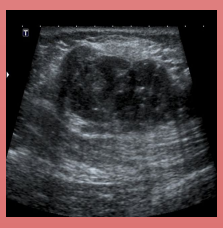

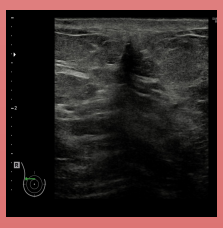

TUBERCULOSIS

REF (10)

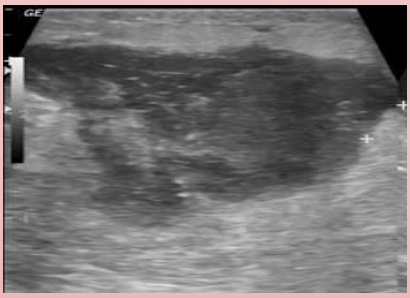

Tuberculosis mastitis can be a challenging diagnosis, and often presents with clinical and imaging findings that are suspicious for malignancy.[9,11]

The clinical manifestations of active TB such as night sweats, fever and weight loss may only be present in a low number of patients. In younger patients, classic infectious symptoms such as breast abscesses may appear. The most common locations in the breast are the central and upper outer quadrant.[9,11]

Tuberculous mastitis most frequent mode of infection is spread from the axillary nodes. Dissemination hematogenously is another source to the breast. Appearances can present as nodular,diffuse and sclerosing. [9]

Imaging findings of TB are non specific. It can present as an asymmetry or mass mammographically, and as an irregular hypoechoic mass on ultrasound with or without internal vascularity.

The nodular type, manifests as an ill defined or irregular mass. The diffuse type can simulate inflammatory carcinoma with skin thickening, and the sclerosing type can be associated with areas of architectural distortion. [9,11]

The gold standard if TB mastitis is suspected is the Ziehl-Neelsen stain and culture for detection of acid fast bacilli performed ideally through core biopsy sonographically. [2,9,11]

It is important to consider this entity in any patient who presents with a breast granulomatous process and may have had an exposure to TB along with other risk factors such as being immunosuppressed.

GRANULAR CELL TUMOUR

Ref (12) image below

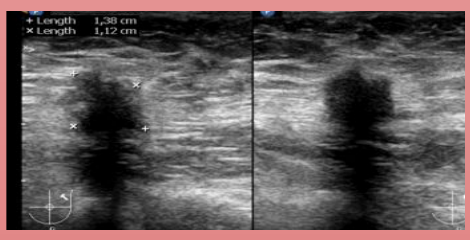

Granular Cell Tumour is a benign neoplasm most commonly seen in the head and neck, with breast accounting for <10%. It is assumed this entity originates from peripheral nerves in the lobular breast unit and is a benign neoplasm derived from perineural Schwann cells of peripheral nerves.it does not pose a higher risk of developing breast cancer [2,13,14]
Most Granular Cell Tumours are benign with insidious onset and slow growth. Approximately 1-2% can undergo malignant transformation.[13,14]
In the breast, it can present as a painless mass, or as a firm mobile lump. Clinically and on imaging, the appearances can mimic carcinoma.[2,13]
Typical appearance mammographically presents as a spiculated mass . On ultrasound this can present as an irregular or ill defined mass with posterior acoustic shadowing. This entity can also have non-specific features including a circumscribed oval mass associated with posterior enhancement depending on the extent of infiltration and degree of reactive fibrosis.[13,14]

Histopathological and immunohistochemical findings are essential for accurate diagnosis and proper treatment.
Treatment of this tumour involves wide local excision. Incomplete excisions can cause local recurrence.
If Granular Cell tumour undergoes a malignant transformation, treatment approach is similar to other malignant breast tumours with poor outcome and prognosis. [13,14]

FIBROMATOSIS

Fibromatosis which are also known as desmoid tumours, are benign locally aggressive tumours arising from fibroblasts and myofibroblasts in the breast parenchyma or from the pectoralis muscular layer. [15,16,17]

The definite etiology of it is unclear and in the breast it occurs in 0.2% of breast neoplasms with a higher rate of occurrence in patients with prior surgical breast augmentation or Gardner's syndrome. [15,16,17]

Clinically this can present as a firm mass with skin dimpling and nipple retraction in superficial and retroareolar tumours.[2,15,16,17]

Mammographically this can present as an irregular or even spiculated dense mass sometimes with parenchymal distortion.

Sonographically this tumour may present as a microlobulated or irregular hypoechoic mass with posterior acoustic shadowing. [2,15,16,17]

Sonographic appearances may also show an irregular heterogeneous predominantly hyperechoic mass with some internal vascularity.

Although this is a rare entity, consideration should be made of breast fibromatosis when there is a past history of surgery or breast augmentation of silicone implants. [17]

Wide local excision with adequate surgical resection and safety margins is advisable as this benign tumour poses high recurrence rate.

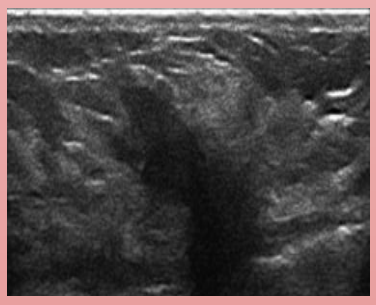

Conclusion

- Always be mindful of mammographic and sonographic appearances.
- Obtain as much relevant medical clinical history as possible.
- Offer differentials in your report and acquire cytology/histology for evaluation and correlation.

REFERENCES

1.Kim, Y.R., Kim, H.S. and Kim, H.W., 2015. Are irregular hypoechoic breast masses on ultrasound always malignancies?: a pictorial essay. Korean journal of radiology, 16(6), pp.1266-1275.

2.Kopans, D.B., 2007. Breast imaging. Lippincott Williams & Wilkins.

3.Kim, Y.R., Kim, H.S. and Kim, H.W., 2015. Are irregular hypoechoic breast masses on ultrasound always malignancies?: a pictorial essay. Korean journal of radiology, 16(6), pp.1266-1275.

4.Ng, W.K., Chan, S.K., Kwok, K.M. and Fung, P.Y., 2019. Diabetic mastopathy: a breast carcinoma mimic. Hong Kong Medical Journal, 251, p.e1.

5.https://www.google.com/url?sa=i&source=images&cd=&cad=rja&uact=8&ved=2ahUKEwiTTKKkuK3kAhVMzYUKHbSAuQQjRxQIBQ&url=https%3A%2F%2Fradiopaedia.org%2Fcases%2Fdiabetic-mastopathy-2&psig=AOvVaw1kR2n_8FnDveFlmJaAr9HU&ust=1567352148190105

6.Wilson, A.R.M., 1995. Ultrasound diagnosis of breast diseases: Tohno, Cosgrove and Sloane 1994. Churchill Livingstone pp 203 ISBN 0 443 04387 6. The Breast, 4(1), p.76.

7.Vasei, N., Shishegar, A., Ghalkhani, F. and Darvishi, M., 2019. Fat necrosis in the Breast: A systematic review of clinical. Lipids in health and disease, 18(1), p.139.

8.Image Source: https://radiopaedia.org/cases/fat-necrosis-breast-4

9.Qiao, Y., Hayward, J.H., Balassanian, R., Ray, K.M., Joe, B.N. and Lee, A.Y., 2018. Tuberculosis mastitis presenting as bilateral breast masses. Clinical imaging, 52, pp.28-31.

10.https://www.google.com/url?sa=i&source=images&cd=&cad=rja&uact=8&ved=2ahUKEwir_IhowK3kAhUqxoUKHQ7GBMQjhxQIBQ&url=https%3A%2F%2Fradiopaedia.org%2Articles%2Fbreast-abscess&psig=AOvVaw0NfLmTbS6-90mZQ2NfeEust=1567356535370738

11.Prapruttam, D., Hedgire, S.S., Mani, S.E., Chandramohan, A., Shyamkumar, N.K. and Harisinghani, M., 2014, June. Tuberculosis—the great mimicker. In Seminars in Ultrasound, CT and MRI (Vol. 35, No. 3, pp. 195-214). WB Saunders.

12.https://www.google.com/url?sa=i&url=https%3A%2F%2Fwww.researchgate.net%2Figure%2EUltrasound-images-of-the-spiculated-mass-seen-on-the-mammogram_fig1_235756919&psig=AOvVaw3Ub6oVJDmbwe9TcvvPoOGa&ust=1580574615118000&source=images&cd=vfe&ved=0CAIQjRxqFwoTCMCqvMGhnucCFQAAAAAdAAAAAABAK

13.Jaganathan, D.M., 2015. Benign granular-cell tumor of the breast: Case report and literature review. Radiology case reports, 10(2), p.1116.

14.Goldbach, A., Gupta, Y., Caroline, D., Malik, A. and Pascarella, S., 2019. Granular cell tumor: The Great Mimicker. The breast journal, 25(3), pp.521-522.

15.Steadman, L. and Crook, S., 2018. Fibromatosis arising from the pectoralis major muscle mimicking breast cancer. Radiology case reports, 13(6), pp.1174-1178.

16.Abdelwahab, K., Hamdy, O., Zaky, M., Megahed, N., Elbalka, S., Elmetwally, M. and Denewer, A., 2017. Breast fibromatosis, an unusual breast disease. Journal of Surgical Case Reports, 2017(12), p.rjx248.

17.Ganau, S., Frigola, G., Bargallò, X., Alonso, I. and Fernández, P.L., 2019. Breast fibromatosis: Variability among imaging methods. The breast journal, 25(4), pp.750-752.

18.https://www.google.com/url?sa=i&source=images&cd=&cad=rja&uact=8&ved=0ahUKEwiU0pXt5fnAhUvQhUIHkqCWUCMwh-KBQxFA&url=https%3A%2F%2Fwww.sciencedirect.com%2Fscience%2Farticle%2Epii%2FS1930043317303345&psig=AOvVaw2WOqbsLBYx56NR-u39Fvr&ust=1572756726268388&cvid=3&uact=8